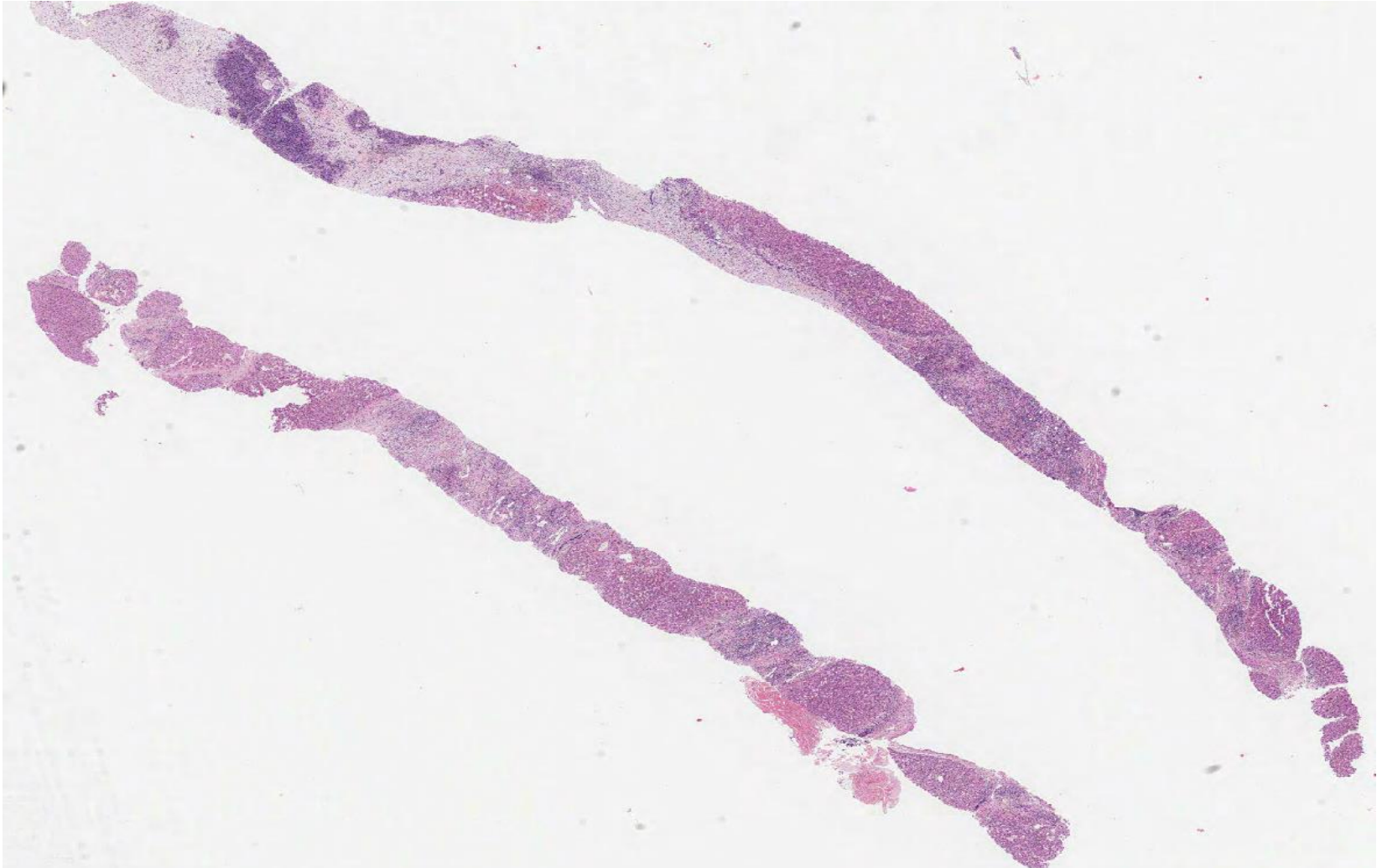


Case LS5 63M

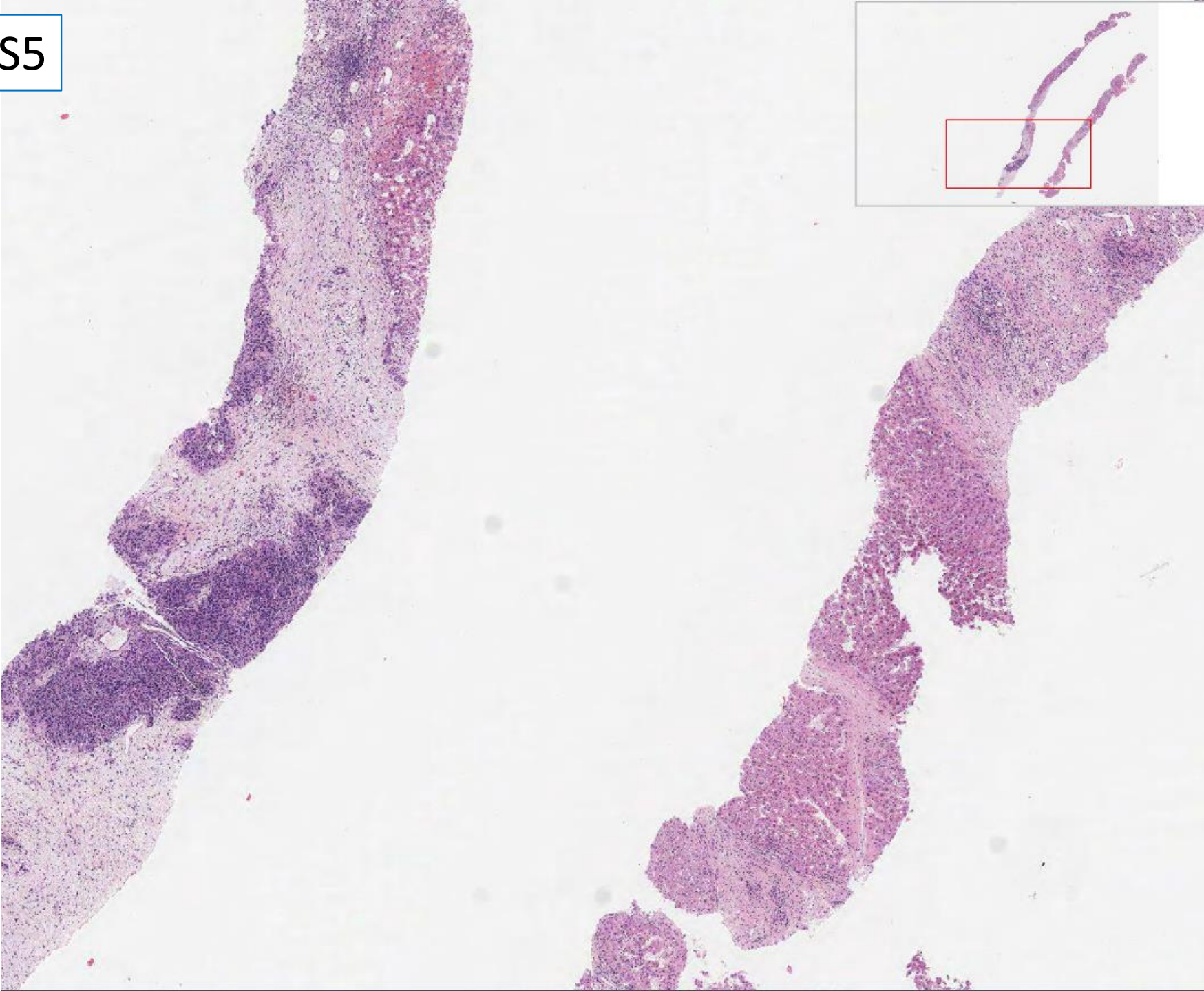
MRI shows focal lesion.in segment 4 which has grown.

? HCC or cholangiocarcinoma. AFP not raised

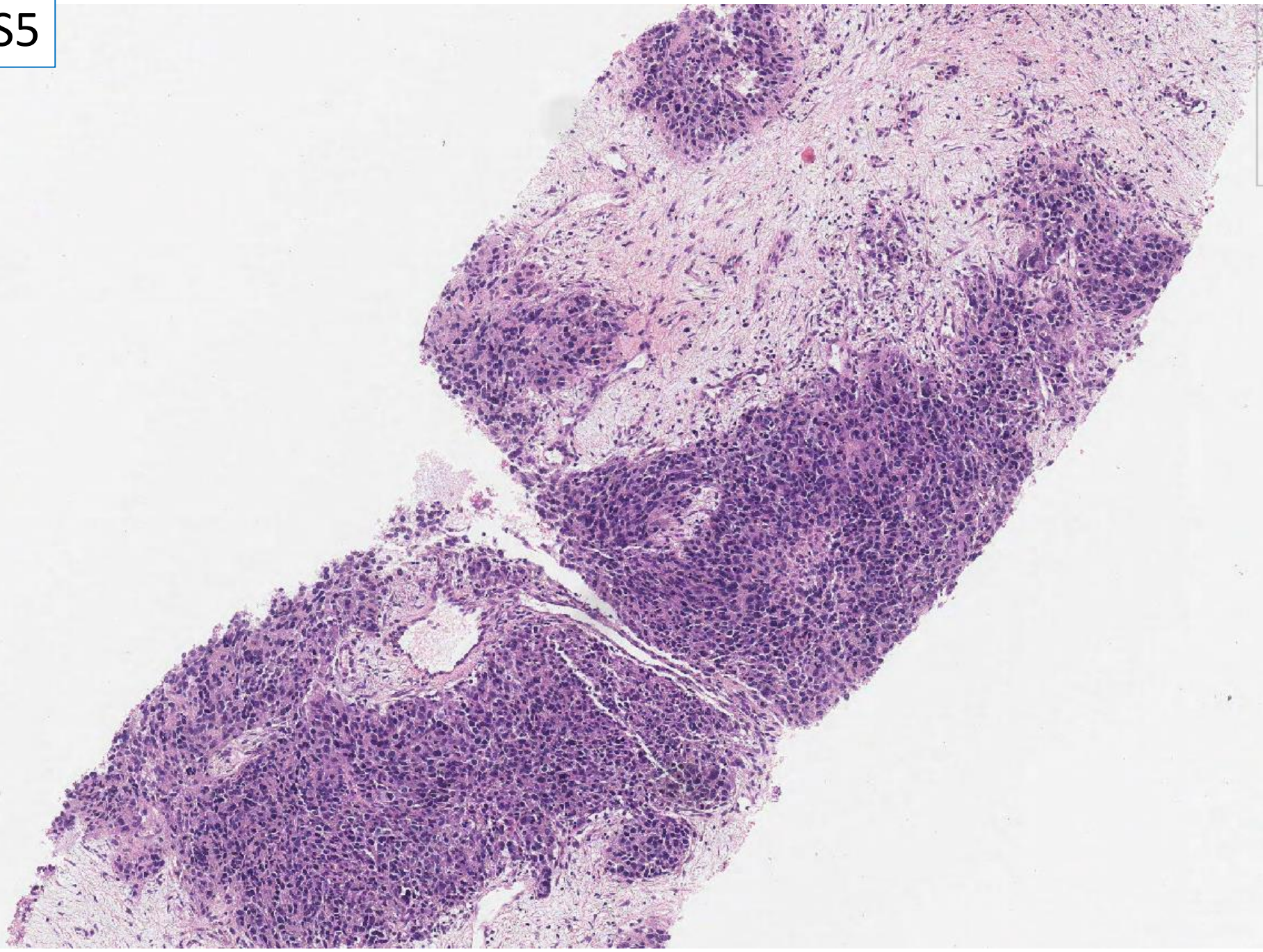
Targeted liver biopsy. Also HepPar1, AE1/AE3, CK19, CD34



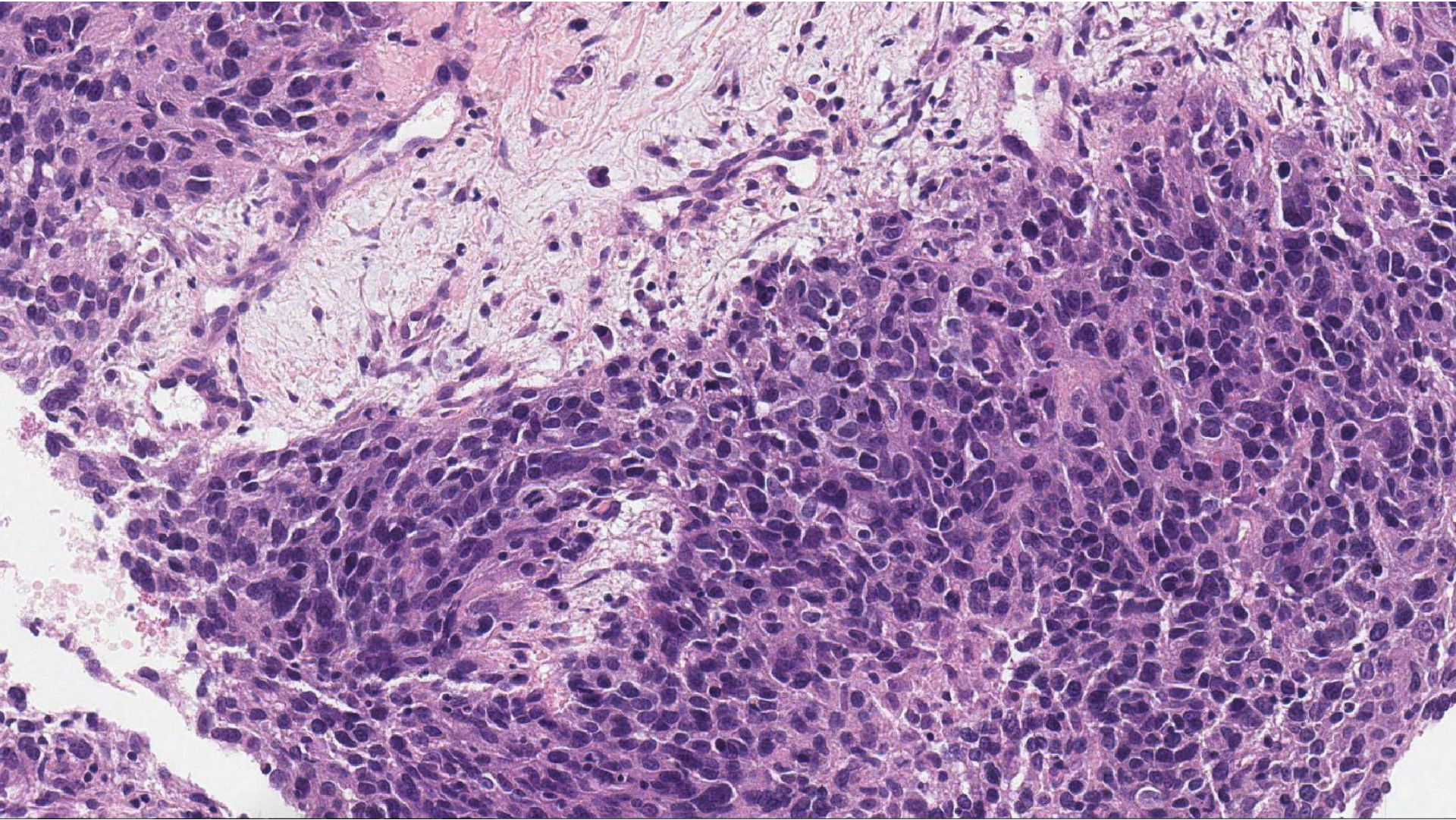
LS5



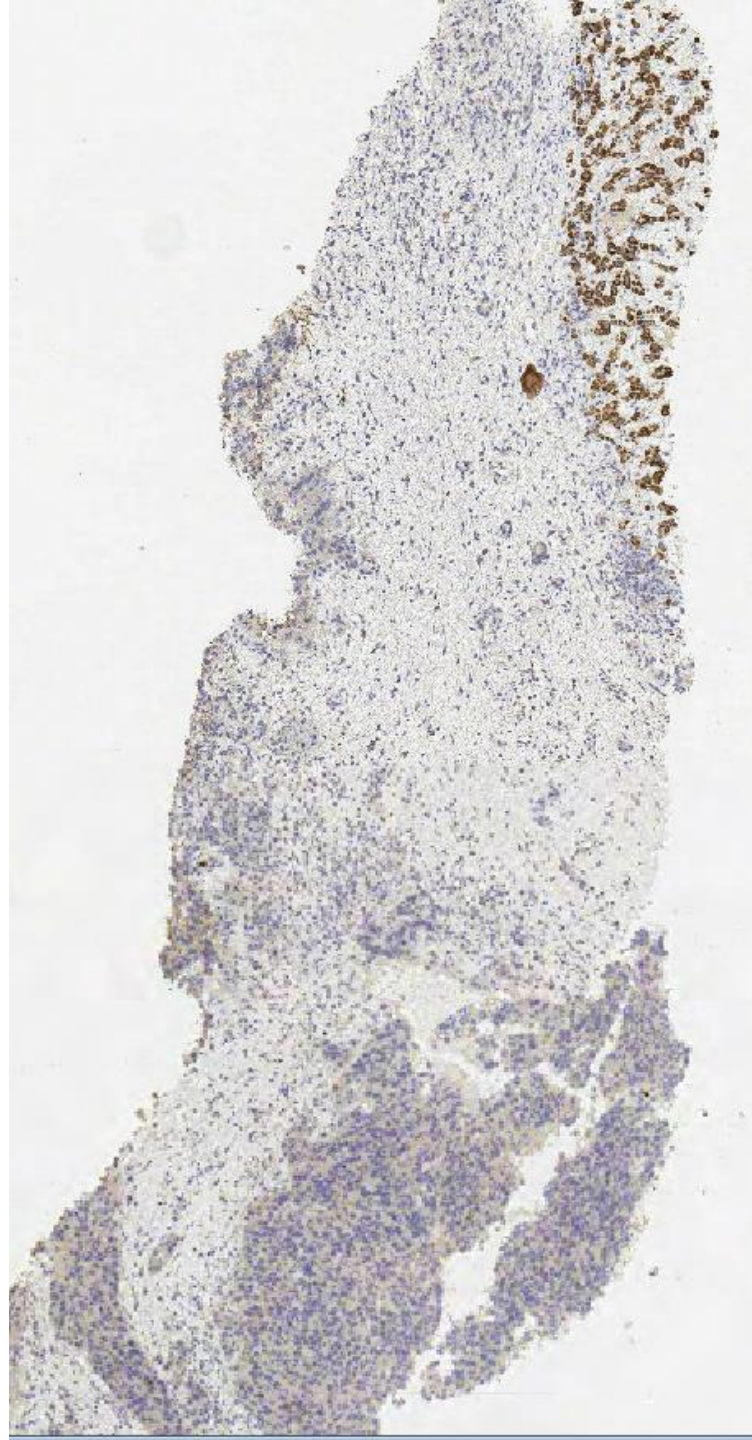
LS5



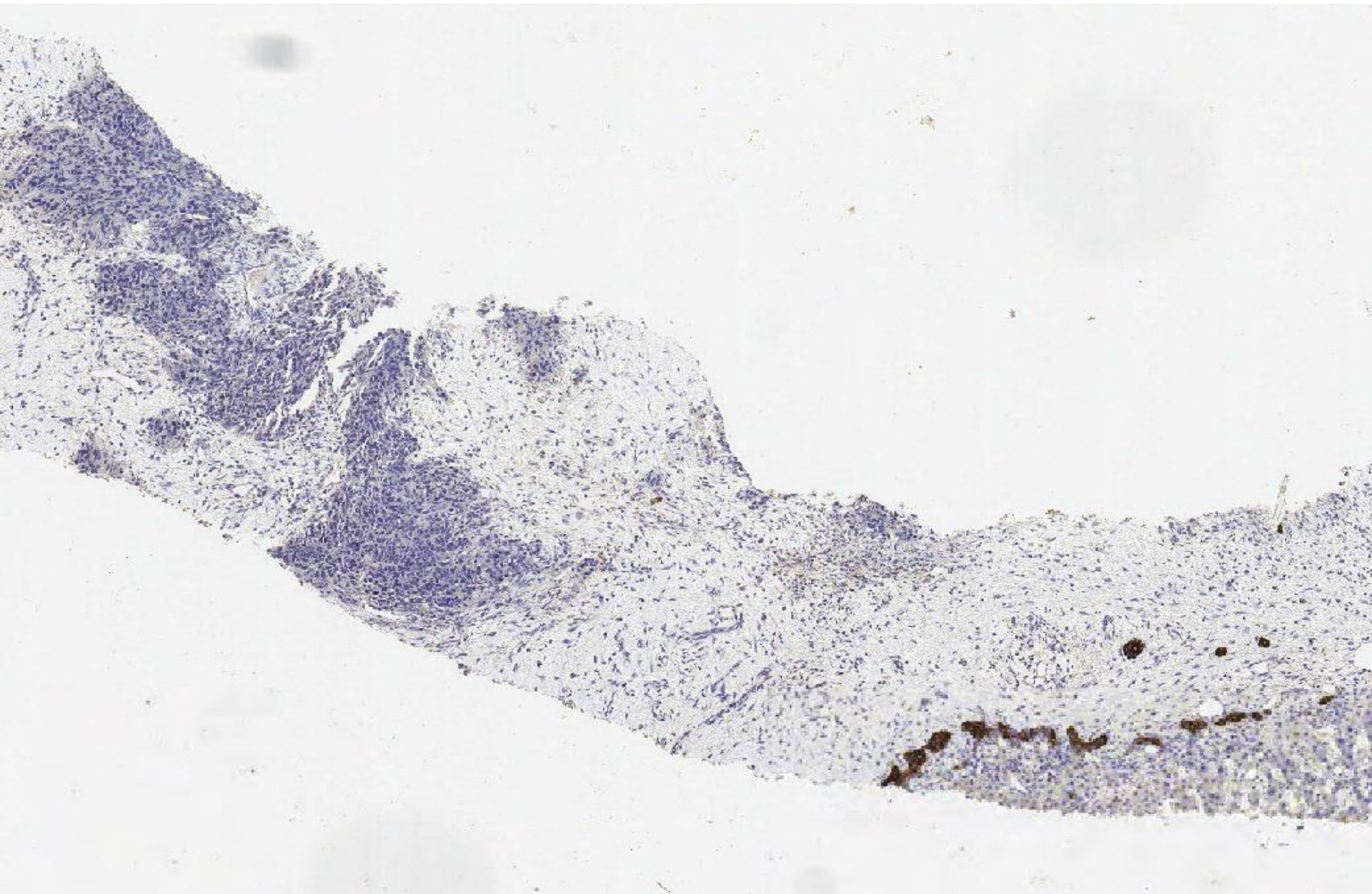
LS5



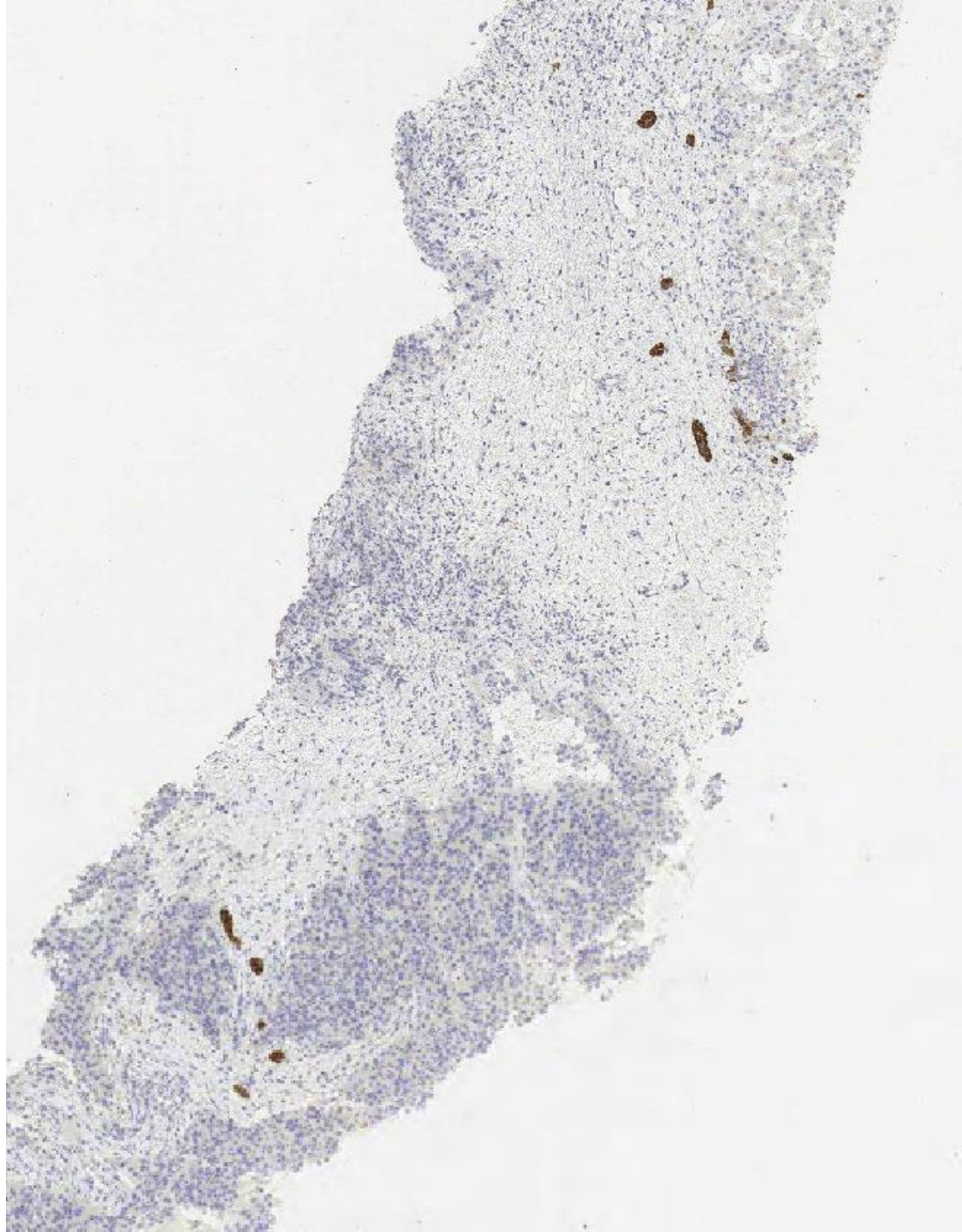
LS5 heppar1



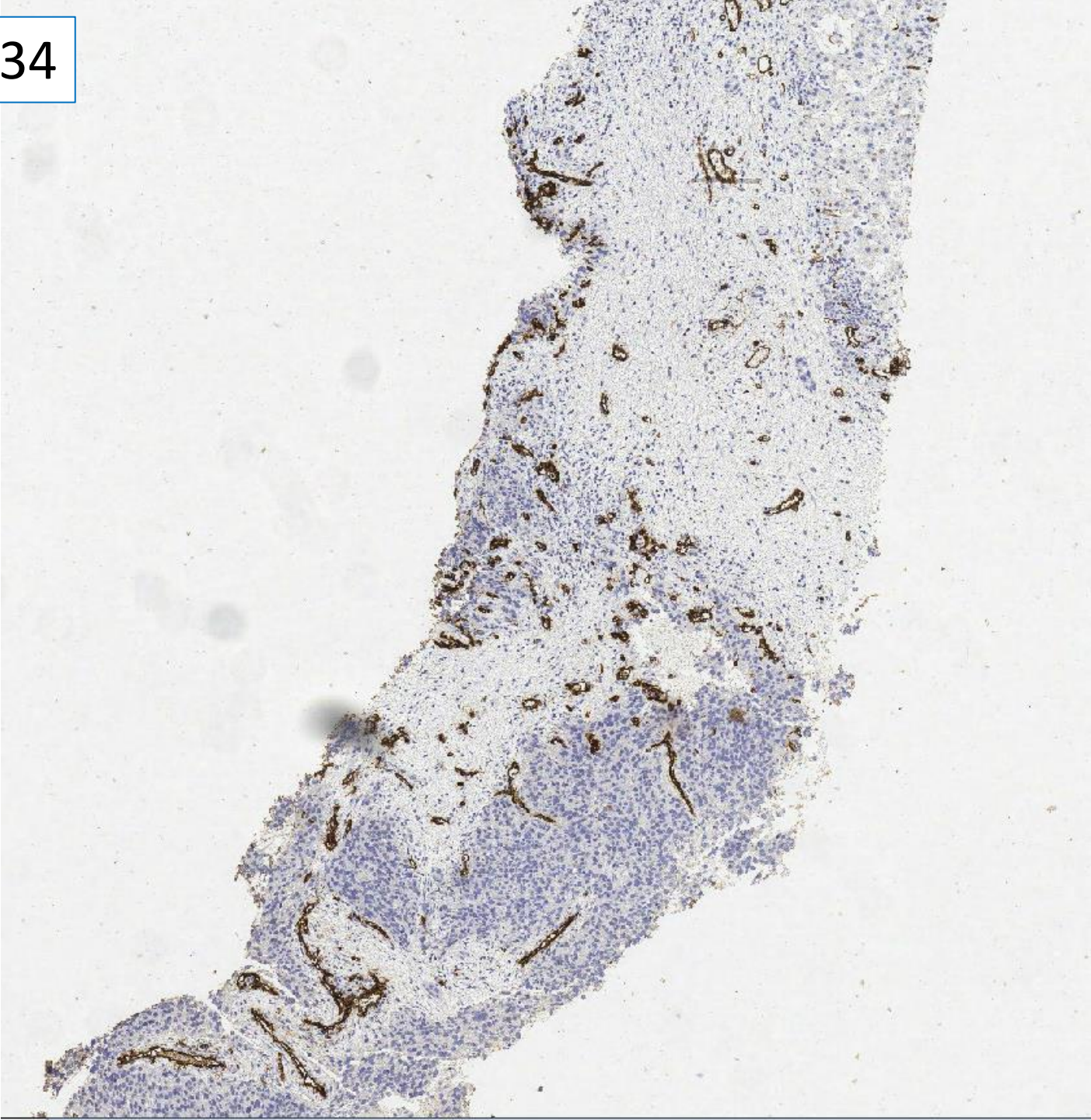
LS5 AE1 AE3



LS5 CK19



LS5 CD34



Case LS5 63M

MRI shows focal lesion.in segment 4 which has grown.

? HCC or cholangiocarcinoma. AFP not raised

Targeted liver biopsy. Also HepPar1, AE1/AE3, CK19, CD34

A	Hepatocellular carcinoma and cirrhosis
B	Malignant tumour (needs more work) and cirrhosis
C	Cholangiocarcinoma and cirrhosis
D	Hepatocellular carcinoma no background liver disease
E	Favour metastasis to a cirrhotic liver (e.g. melanoma, sarcoma)